

## Complex regional pain syndrome type-I after rubella vaccine

Hakan Genc \*, Aynur Karagoz, Meryem Saracoglu, Ebru Sert, Hatice Rana Erdem

*Ministry of Health, Ankara Education and Research Hospital, 2nd Department of Physical Medicine and Rehabilitation, 06340, Cebeci, Ankara, Turkey*

Received 21 June 2004; accepted 8 November 2004  
Available online 18 December 2004

### Abstract

Complex regional pain syndrome type I (CRPS-I) is a complex disorder characterised by pain, autonomic dysfunction, and decreased range of motion. The syndrome was believed as a well-recognized disorder in adults but, less commonly recognized in children. CRPS-I after vaccination has been rarely reported. We reported an 11-year-old young girl with CRPS-I due to rubella vaccine.

© 2004 European Federation of Chapters of the International Association for the Study of Pain. Published by Elsevier Ltd. All rights reserved.

**Keywords:** Complex regional pain syndrome; Children; Vaccination

### 1. Introduction

Complex regional pain syndrome type I (CRPS-I) is a complex clinical disorder of one or more extremities associated with neurovascular disturbance and dystrophic changes of the skin and bones. Common predisposing conditions include trauma, infection, surgery, cervical radiculopathy, soft tissue contusions, fractures, tendon ruptures and myocardial infarction. CRPS-I is characterized by severe pain, allodynia or hyperalgesia, edema, limited range of motion, and vasomotor instability. The pain is often burning in quality (Dijkstra et al., 2003; Strakowski et al., 2000).

In recent years, CRPS-I has been recognized with increasing frequency in children. The pathogenesis of CRPS-I is not well understood. The diagnosis is ordinarily made on a clinical basis. There is no pathognomonic laboratory finding for CRPS. Triple phase bone scan can show increased uptake in the involved limb

early in the process. Multidisciplinary treatment combining TENS, physical therapy, psychotherapy using behavior modification techniques, and oral medications is effective in most children (Desparmet-Sheridan, 2000; Dijkstra et al., 2003; Strakowski et al., 2000).

CRPS-I after vaccination has been rarely reported. We reported an 11-year-old young girl with CRPS-I due to rubella vaccine.

### 2. Case report

An 11-year-old girl was admitted with severe pain, swelling and limited range of motion of the left hand. She had been received rubella vaccination in the left arm one week before. Twenty minutes later, she developed painless swelling, discoloration and limited range of motion of her left hand. There was no history of trauma prior to immunization. All other immunizations had been well tolerated. Initially she had visited an orthopedist and she had been given non-steroidal anti-inflammatory drug therapy. Her symptoms and signs did not

\* Corresponding author. Tel./fax: +90 312 4688171.  
E-mail address: [hakangenc06@hotmail.com](mailto:hakangenc06@hotmail.com) (H. Genc).

resolve with this therapy within one week and severe pain was added to her symptoms.

On physical examination, her left hand was edematous, warm and had limited range of motion. Tenderness was maximal at the wrist and digits. Sensation to light touch was normal, and there was no paresthesia or hyperesthesia. Capillary refill and pulses were normal in the left arm. The remainder of the physical examination including the left elbow and shoulder and also other upper and lower limbs were normal. All the following studies were normal, including erythrocyte sedimentation rate, hemoglobin, white blood cell count, blood chemistry, thyroid-stimulating hormone level, X-rays of the left hand, nerve conduction velocity (NCV) studies and computerised tomogram (CT) of the cervical spine. Triple phase bone scan showed increased uptake in the left hand (Fig. 1). The patient was also evaluated by an experienced psychiatrist. He reported that the patient had relationship problems with her parents. The quality of the pain, objective findings on skin examina-

tion, and triple phase bone scan findings were consistent with the diagnosis of CRPS-I. She was undergone physical therapy and psychotherapy. Improvement was observed with this therapy within 4 weeks.

### 3. Discussion

A variety of terms have been used to describe CRPS. The most frequently used term is reflex sympathetic dystrophy (RSD). RSD is a generic term used to describe posttraumatic pain accompanied by inappropriate autonomic activity and impaired extremity function. A wide variety of diagnostic criteria sets were applied in RSD research, most of them focused on sensory and autonomic features (Kozin et al., 1981; Wilder et al., 1992). In 1993, the term CRPS was introduced to replace the term RSD. The term CRPS, provides a descriptive terminology based on clinical findings, location and specifics of the injury, without implying mechanism, cause or sympathetic maintenance. In 1994, Merskey and Bogduk published the CRPS criteria in a book produced by the International Association for the Study of Pain (IASP) (Table 1) in which a note was added that the presence of an inciting event wasn't mandatory for the diagnosis (Merskey and Bogduk, 1994). Conversely, in the summary statement of the consensus meeting by Stanton-Hicks et al., this note was not added to the criteria (Stanton-Hicks et al., 1995). According to the published criteria for the diagnosis of CRPS-I, it seems likely that the syndrome was precipitated by rubella vaccination in our patient. Additionally, the quality of the pain and objective findings on skin examination were consistent with the diagnosis of CRPS-I.

CRPS is a well-recognised disorder in adults. The estimated female preponderance varies from 1:1.6 to 4.5:1. Age at onset is most frequently between 30 and 55 years (mean 40). An identifiable nociceptive injury is diagnosed in less than 50% of cases (Koman et al., 2002). Upper extremity was involved most often in the adults (Desparmet-Sheridan, 2000). Some of the features of CRPS represented in adults, seem not to be fully rep-

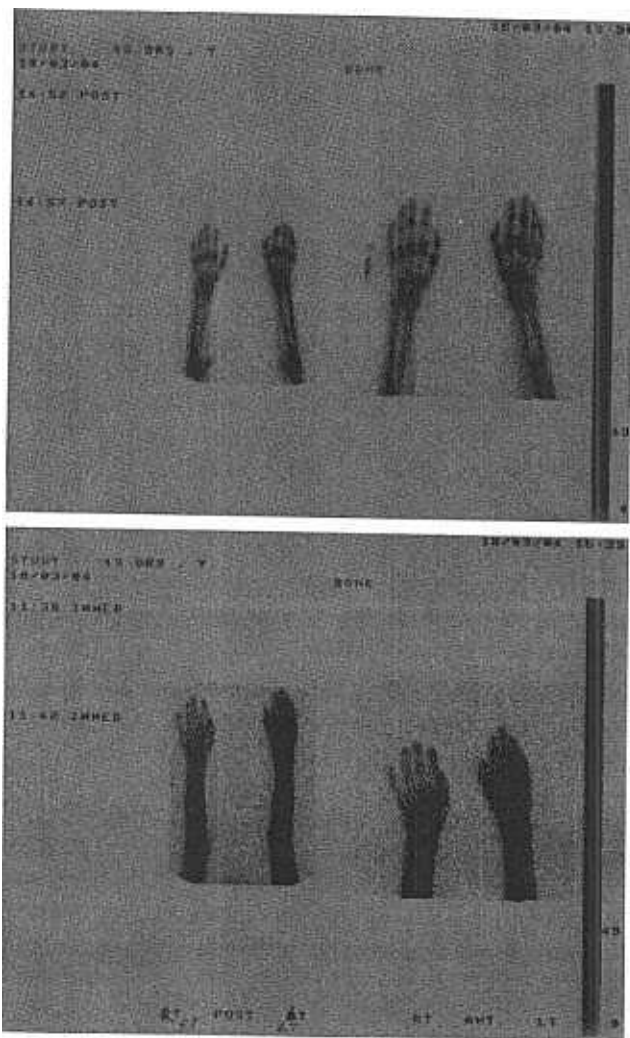


Fig. 1. Triple phase bone scan images of the patient showing increased uptake in the left hand.

Table 1

Diagnostic criteria for CRPS proposed by Merskey and Bogduk (Merskey and Bogduk, 1994)

#### Chronic regional pain syndrome, type I

- |   |   |
|---|---|
|   | Presence of an initiating noxious event or a cause of immobilization  |
| 2 | Continuing pain, allodynia, or hyperalgesia with which pain is disproportionate to any inciting event                 |
| 3 | Evidence at some time of edema, changes in skin blood flow, or abnormal sudomotor activity in the region of the pain  |
| 4 | Diagnosis was excluded by existence of conditions that would otherwise account for the degree of pain and dysfunction |

Note. criteria 2–4 must be satisfied.

resented in pediatric cases. The majority of children with CRPS-I are girls (54.5% to 84%) and reported age range is 5–18 years (Laxer et al., 1985; Wilder et al., 1992; Cimaz et al., 1999). There is an identifiable precipitating factor in most of children and lower extremity is the most affected part of the body (Silber and Majd, 1988; Laxer et al., 1985; Wilder et al., 1992). Wilder et al. examined the predictive values of several risk factors in children with CRPS-I and reported that younger patients had a milder course than older ones. They also stated that, a younger age correlated with less pain, better function, fewer remaining signs of autonomic dysfunction on follow-up and a shorter total duration of symptoms (Wilder et al., 1992). Accordingly, improvement was observed with physical therapy and psychotherapy within 4 weeks and no remaining sign of autonomic dysfunction was observed on follow-ups.

Psychological disturbances may be predisposing or contributing factors to this syndrome (Cassidy and Petty, 1995). Sometimes a particular psychological profile can be seen in children with CRPS-I. The children are intelligent, driven overachievers who are involved in very competitive activities and who often react to the loss of this activity with depression. Other psychological issues such as family discord or divorce and enmeshment with one parent are found (Desparmet-Sheridan, 2000). Walsh reported that, the therapist must remember the emotional and psychologic component to this syndrome, and this component must be included in the treatment plan (Walsh and Muntzer, 2002). Accordingly, our patient had relationship problems with her parents, and she responded psychotherapy.

CRPS-I may be precipitated by a number of factors, including trauma, infection, surgery, soft tissue contusions, fractures, tendon ruptures and burns. Minor trauma is the most frequently identified factor. To our knowledge, this is the first report of CRPS-I after rubella vaccine. Rubella vaccine contains live attenuated rubella virus grown in human diploid cells (RA 27/3). Known adverse events associated with rubella vaccine include low-grade fever and rash in 5–10% of recipients and joint pains with or without objective manifestation of arthritis. With regard to other illnesses related to rubella vaccine, the Institute of Medicine (IOM) concluded that the evidence was insufficient to implicate rubella vaccine as a cause of thrombocytopenic purpura, radiculoneuritis, and other neuropathies (Orenstein et al., 2000). Clinical signs were not consistent with these adverse events in our patient. The diagnosis of radiculoneuritis or neuropathies was excluded with both the NCV studies and CT findings of the cervical spine. Additionally, clinical signs of our patient were not typical of an allergic response. In the light of these clinical data, we thought that the reaction did not result from side effects due to vaccine constituent. In a previous study, Jastaniah et al. reported four cases of CRPS-I after hepatitis B vac-

ination. They stated that the reaction may result from injection trauma or may be an allergic response to a vaccine constituent. However, they also reported that the symptoms were not preventable by premedication with antihistamines in one patient on two occasions, and the signs were not typical of an allergic response. Relation was not reported between the symptoms of the CRPS-I and adverse effects of the vaccine (Jastaniah et al., 2003). CRPS-I was precipitated by rubella vaccine in our patient, which includes different constituent from hepatitis B vaccine. Clinical signs of the CRPS-I in both Jastaniah's cases and ours were not attributed to the adverse events due to vaccine constituent. So, we thought that the reaction most likely resulted from injection trauma as an initiating noxious event in both Jastaniah's cases and ours.

In conclusion, a child with CRPS-I, thought to be due to an injection trauma, after rubella vaccine is presented. We thought that, in children who developed swelling, skin changes and limited range of motion on hands or feet after a vaccination or an injection, the diagnosis of CRPS-I should be kept in mind.

## References

- Cassidy JT, Petty RE. Musculoskeletal pain syndromes of nonrheumatic origin. In: Textbook of pediatric rheumatology. 3rd ed.. Philadelphia: W.B. Saunders Company; 1995. p. 108–32.
- Cimaz R, Maticci-Cerinic M, Zulian F, Falcini F. Reflex sympathetic dystrophy in children. *J Child Neurol* 1999;14:363–7.
- Desparmet-Sheridan JF. Pain in children. In: Raj PP, editor. Practical management of pain. 3rd ed.. St. Louis: Mosby; 2000. p. 295–315.
- Dijkstra PU, Groothoff JW, Jan ten Duis H, Geertzen JHB. Incidence of complex regional pain syndrome type I after fractures of the distal radius. *Eur J Pain* 2003;7:457–62.
- Jastaniah WA, Dobson S, Lugsdin JG, Petty RE. Complex regional pain syndrome after hepatitis B vaccine. *J Pediatr* 2003;143:802–4.
- Koman LA, Smith BP, Smith TL. Reflex sympathetic dystrophy (complex regional pain syndromes-types 1 and 2). In: Mackin EJ, Callahan AD, Skirven TM, Schneider LH, Osterman AL, Hunter JM, editors. Rehabilitation of the hand and upper extremity. 5th ed.. St. Louis: Mosby; 2002. p. 1695–706.
- Kozin F, Ryan LM, Carrera GF, Soin JS, Wortmann RL. The reflex sympathetic dystrophy syndrome III: scintigraphic studies, further evidence for the therapeutic efficacy of systemic corticosteroids, and proposed diagnostic criteria. *Am J Med* 1981;70:23–30.
- Laxer RM, Allen RC, Malleson PN, Morrison PT, Petty RE. Technetium 99m-methylene diphosphonate bone scans in children with reflex neurovascular dystrophy. *J Pediatr* 1985;106(3):437–40.
- Merskey H, Bogduk N. Complex regional pain syndromes: classification of chronic pain. Descriptions of chronic pain syndromes and definitions of pain terms. Seattle: IASP Press; 1994. p. 40–3.
- Orenstein WA, Wharton M, Bart KJ, Hinman AR. Immunization. In: Mandell GL, Bennett JE, Dolin R, editors. Principles and practise of infectious diseases. 5th ed.. Philadelphia: Churchill Livingstone; 2000. p. 3207–34.
- Silber TJ, Majd M. Reflex sympathetic dystrophy syndrome in children and adolescents. *AJDC* 1988;142:1325–30.
- Stanton-Hicks M, Janig W, Hassenbusch S, Haddock JD, Boas R, Wilson P. Reflex sympathetic dystrophy: changing concepts and taxonomy. *Pain* 1995;63:127–33.

Strakowski JA, Wiand JW, Johnson EW. Upper limb musculoskeletal pain syndromes. In: Braddom RL, editor. *Physical medicine and rehabilitation*. 2nd ed.. W.B. Philadelphia: Saunders Company; 2000. p. 792–818.

Walsh MT, Muntzer E. Therapist's management of complex regional pain syndrome (reflex sympathetic dystrophy). In: Mackin EJ,

Callahan JM, Skirven TM, Schneider LH, Osterman AL, Hunter JM, editors. *Rehabilitation of the hand and upper extremity*. 5th ed.. St. Louis: Mosby; 2002. p. 1707–24.

Wilder RT, Berde BC, Wolohan M, Vieyra MA, Masek BJ, Micheli LJ. Reflex sympathetic dystrophy in children. *J Bone Jt Surg* 1992;74-A(6):910–9.