

0305-4179(95)00139-5

# Reflex sympathetic dystrophy after a burn injury

L. van der Laan and R. J. A. Goris

Department of Surgery, University Hospital Nijmegen, Nijmegen, The Netherlands

*Reflex sympathetic dystrophy (RSD) is a disease that can appear after minor trauma or operation to an extremity. The injury may vary from a simple contusion to a fracture. The prevalence of burns as a cause of RSD, within a population of 829 patients with RSD, was studied retrospectively. Prospectively, we documented the medical history, signs and symptoms of all patients with RSD, seen by our department during the period from January 1984 to 31 December 1994. Four patients had developed RSD after a burn injury, resulting in a prevalence of 0.5 per cent. Though the clinical signs of early RSD are similar to those of a (thermal) burn, alertness to recognize inflammatory signs, in combination with the increase in complaints after exercise, is necessary for early diagnosis and treatment of the complicating RSD. Copyright © 1996 Elsevier Science Ltd for ISBI.*

Burns, Vol. 22, No. 4, 303–306, 1996

## Introduction

Reflex sympathetic dystrophy (RSD) is a complication occurring after even minor injury or operation to an extremity. It is a major cause of disability and pain, and may result in permanent loss of function of the extremity, or even in unemployment of the patient. RSD has various names, depending on the country concerned, the precipitating factor, or the specialty treating the patient. Other denominations for RSD are Sudeck's atrophy, algodystrophy, causalgia, postinfarction sclerodactylia, Pourfour du Petit syndrome, peripheral trophoneurosis or Babinsky-Froment sympathetic paralysis.

The reported incidence of RSD is 1–2 per cent after various fractures<sup>1</sup>, 2–5 per cent after peripheral nerve injury<sup>2</sup> and 7–35 per cent in a prospective study of Colles fracture<sup>3</sup>. Veldman et al.<sup>4</sup> prospectively studied a large population of patients with RSD ( $n=829$ ). Within this well-documented population, RSD resulted from trauma in 65 per cent, from operation in 19 per cent, from an inflammatory process in 2 per cent and from various other precipitant factors in 4 per cent. In 10 per cent of the patients, RSD occurred spontaneously. The pathogenesis of RSD has been linked to an abnormal sympathetic nervous reflex. However, interference with the sympathetic system by regional guanethidine infusion, sympathetic blocs or sympathectomy, has not been found to be invariably effective<sup>5–7</sup>.

Sudeck was the first to describe RSD in term of an exaggerated inflammatory response to injury or operation<sup>8</sup>. Recently, several studies provided new evidence

supporting the inflammatory theory<sup>9,10</sup>, which suggested a role for toxic oxygen radicals in its pathogenesis<sup>11–14</sup>. Also, in the early phase of RSD the affected extremity is swollen, the skin is erythematous and feels warm, while unexplained diffuse pain is present and the range of active motion is limited. These signs and symptoms of early RSD are similar to those found in superficial- and partial-thickness skin burns<sup>15</sup>. Contrary to the burn wounds, the signs and symptoms of RSD increase when the involved extremity is used. At a latter stage of RSD oedema may be absent, while soft tissue atrophy becomes apparent. In our large, well-documented population of RSD patients, we studied the subgroup of patients developing RSD after a burn injury retrospectively, as to prevalence, signs, and symptoms. Also, two case reports are described.

## Patients and methods

All new patients presenting at the outpatient clinic of the Department of Surgery, University Hospital Nijmegen, were examined prospectively for signs and symptoms of RSD. For the diagnosis RSD, the following criteria were utilized<sup>4</sup>.

1. At least four out of five of the following:
  - unexplained diffuse pain;
  - difference in skin colour compared with the other extremity;
  - diffuse oedema;
  - difference in skin temperature compared with the other extremity;
  - limited active range of motion.
2. Occurrence or increase of the above signs and symptoms after using the extremity.
3. Above signs and symptoms present in an area larger than the area of primary injury or operation and including the area distal to the primary injury.

Only signs and symptoms definitely present at the time of the first examination were noted. During the period between 1 January 1984 and 31 December 1994, 829 patients fulfilled these criteria for RSD. In this file of RSD patients, we studied the subgroup who developed RSD after a burn injury respectively.

## Results

Out of 829 patients with documented RSD, four had developed RSD after a burn injury (*Table I*). All four patients were male, and in all four the upper extremity was

**Table I.** Characteristics of patients who developed RSD after a burn injury

Characteristics	Patient A	Patient B	Patient C	Patient D
Age (yr)	46	22	50	58
Sex	Male	Male	Male	Male
Time trauma – RSD symptoms (weeks)	6	10	11	20
Duration of RSD at first visit (weeks)	1	10	1	225
Localization	Hand	Hand	Hand	Hand
Infection	No	Yes	No	No

**Table II.** Signs and symptoms of RSD, complicating a burn injury, as found at first presentation in our clinic

Signs and symptoms	Patient A	Patient B	Patient C	Patient D
<b>Inflammatory</b>				
Pain	+	++	++	+
Skin colour	Red	Blue	Red	Normal
Oedema	++	++	++	–
Skin temperature	Warm	Cold	Warm	–
Decrease of ROM	++	++	–	–
Increase of complaints after exercise	++	++	++	++
<b>Neurological</b>				
Decreased grip strength	++	++	+	++
Hypoaesthesia	•	+	•	–
Hyperpathy	•	++	++	+
Hyperhidrosis	–	–	+	–
<b>Atrophy</b>				
Atrophy skin	•	•	–	+

– = absent; • = not noted; + = present; ++ = severe.


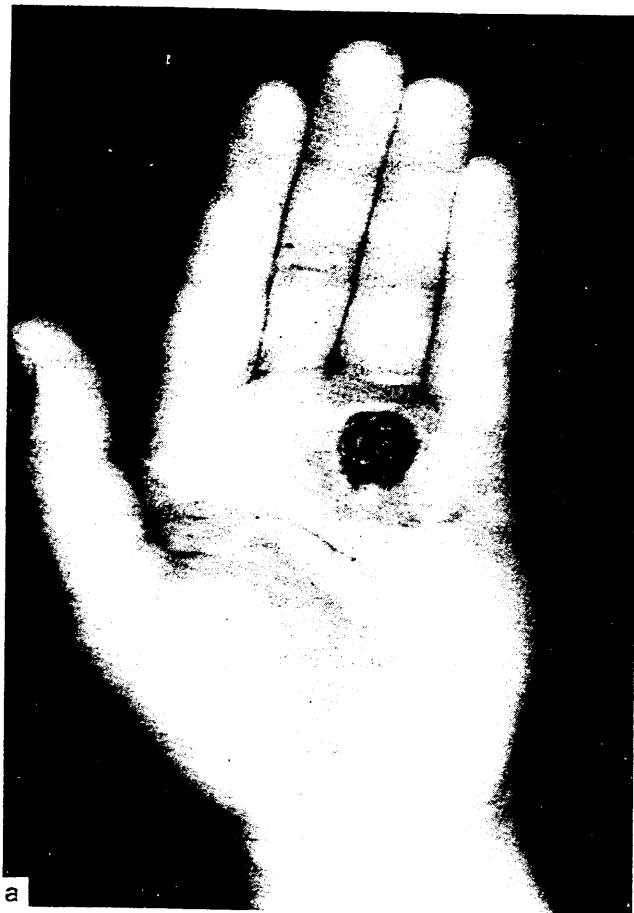
affected. The signs and symptoms of RSD became evident 6–20 weeks after the burn injury. The burn wound was of superficial partial thickness in one patient, and deep partial thickness in three patients. At the onset of RSD, the skin temperature in the affected extremity was abnormally cold in two patients, abnormally warm in one and normal in one patient (Table II). At the first physical examination performed during the first visit to our department, the skin temperature was warm in two patients, cold in one patient, and normal in one patient. In all four patients the grip strength of the affected extremity was diminished. Only one patient showed hypoaesthesia, while all presented with hyperpathy. It is noticeable that patient D did not fulfil the criteria of RSD at his first presentation at our clinic (Table II), when the RSD had been apparent for about 4.5 years (Table I). However, we admitted this patient to the burn wound population complicated with RSD, because the acute inflammatory signs and symptoms of RSD were all present at the physical examination carried out in a peripheral clinic 20 weeks after the burn injury.

## Case reports

Patient A, a 46-year-old man, had a chemical deep partial skin thickness burn injury on the volar side of four fingers of the right hand. One day after the injury the fingers showed some erythema and bullae. The sensibility was normal. Treatment consisted of local application of silver sulphadiazine. The pain disappeared but small areas of necrosis at the distal phalanx of the fifth finger required excision. The wound subsequently healed but the fingers remained stiff. Six weeks later the hand

became warm, swollen, red and slightly painful. These complaints increased with exercise. The range of motion (ROM) and grip strength of the second and third finger were decreased. We diagnosed RSD, and treated the patient locally with dimethyl sulphoxide (DMSO) cream. After 4 months the pain and oedema had disappeared, the skin colour and temperature, ROM and grip strength had returned to normal.

Patient B, a 24-year-old man, presented at another hospital with a deep partial thickness burn wound on the palmar side of the left hand. Due to progressive necrosis, five connective necrotomies were performed which resulted in a non-healing ulcer. Bacterial cultures grew *Enterobacter cloacae*, enterococci, and anaerobic *Peptostreptococcus species*, which were treated with a mixture of amoxicillin and metronidazol for 1 month. After this period, the patient was referred to our department because of non-healing of the deep ulcer. Complaints by the patient consisted of constant pain localized in the hand, increasing with exercise. The palmar side of the hand showed a deep ulcer (Figure 1a) penetrating to the flexor tendon sheaths, with a diameter of 1.5 cm. The hand felt cold, was blue, and moderately swollen. Flexion of the fourth and fifth fingers was limited. Grip strength of the hand was diminished and there was hypoaesthesia of the third to the fifth finger. Our diagnosis was RSD of the hand complicated by an anaerobic infection. The patient was treated with intravenous mannitol (100 g/24 h), metronidazol (3 times a day, 500 mg), gentamycin (twice a day, 120 mg) and verapamil (240 mg/24 h) to improve local blood flow. The ulcer was treated locally with Eusol. Within 1 week, the ulcer was healing, while the swelling disappeared, the colour of the hand normalized, and the pain decreased. The follow-up treatment consisted of N-acetyl cysteine, 600 mg, 3 times a day and



**Figure 1.** a, An ulcer at the palmar side of the hand after a scald burn, complicated by 'cold' RSD and progressive necrosis. b, Four weeks after treatment with hydroxyl scavengers and peripheral vasodilatation.

verapamil. Four weeks later the open wound was closed (Figure 1b). Also, the appearance, and function of the hand had normalized. However, some complaints of pain persisted.

## Discussion

In our population of 829 patients suffering from RSD, only four patients developed this complication after a burn injury. This study, however, does not indicate the prevalence of RSD after burns in general. Noticeable is the fact that RSD after a burn injury was only seen in male patients, while in the total population of RSD patients studied, 76 per cent were female<sup>4</sup>. In all four cases, RSD was localized in the upper extremity, while in the total population RSD affected the upper extremity in 59 per cent<sup>4</sup>. This preferential location may be simply explained by the fact that the hand is the part of the body most frequently burned<sup>16</sup>.

The signs and symptoms of RSD became obvious 6–20 weeks after the burn injury. Despite their similarity to the signs and symptoms of an acute burn, identification of RSD was possible relatively early after the burn injury. Early diagnosis of RSD is important because the success of treatment of RSD depends on its early initiation<sup>12,17</sup>. Treatment of the RSD by interfering with the sympathetic system by intravenous regional sympathetic blockade resulted in no significant differences between guanethidine and placebo<sup>6</sup>. This study was even stopped prematurely because of the severity of the adverse effects. Also, from other studies the outcomes of the sympathectomy were negative<sup>5,7</sup>. Hydroxyl radical scavenger therapy, as

DMSO cream, decreased the complaints of RSD<sup>12–14</sup>. So, the treatment of RSD patients in our clinic uses hydroxyl radical scavengers. The case report of patient B demonstrates that necrotomy and antibiotics were unable to cure the anaerobic infection in an extremity with 'cold' RSD, because tissue perfusion is very poor<sup>18</sup>. The treatment of a burn injury complicated by RSD – as in all cases with acute RSD – should therefore include hydroxyl radical scavengers<sup>12–14</sup> combined with vasodilators.

## Conclusions

RSD is a rare complication of a burn injury to an extremity. Its early signs and symptoms are similar to these of the burn wound itself. Alertness to recognize the inflammatory signs, in combination with the increase of complaints after exercise, is necessary for early diagnosis and treatment of the RSD. The treatment of burn wounds complicated by RSD should consist of the normal treatment for the burn, in combination with the normal treatment of RSD.

## References

- 1 Böhn E. Das Sudecksche Syndrome *Hefte zur Unfallheilkunde* 1985; 174: 241–250.
- 2 Omer GC, Thomas SM. Treatment of causalgia. *Tex Med* 1971; 67: 93–96.

- 3 Atkins RM, Duckworth T, Kanis JA. Features of algodystrophy after Colles fracture. *J Bone Joint Surg* 1990; **72**: 105-110.
- 4 Veldman PHJM, Reynen HM, Arntz IE, Goris RJA. Signs and symptoms of reflex sympathetic dystrophy: prospective study of 829 patients. *Lancet* 1993; **342**: 1012-1015.
- 5 Moesker A, Boersema FP, Schijgrond HW, Cortvriendt W. Treatment of posttraumatic sympathetic dystrophy (Sudeck's atrophy) with guanethidine and ketanserine. *Pain Clin* 1985; **1**: 171-176.
- 6 Jadad AR, Carroll D, Glynn CJ, McQuay HJ. Intravenous regional sympathetic blockade for pain relief in reflex sympathetic dystrophy: a systematic review and a randomized, double-blind crossover study. *J Pain Symp Management* 1995; **10**: 13-20.
- 7 Mailis A, Meindok H, Papagaiou M, Pham D. Alterations of the three-phase bone scan after sympathectomy. *Clin J Pain* 1994; **10**: 146-155.
- 8 Sudeck P. Die sogenannte akute Knochenatrophie als Entzündungsvorgang. *Chirurg* 1942; **15**: 449-458.
- 9 Oyen WJG, Arntz IE, Claessens AMJ, van der Meer JWM, Corstens FHM, Goris RJA. Reflex sympathetic dystrophy of the hand: an excessive inflammatory response? *Pain* 1993; **55**: 151-157.
- 10 Blockx P, Driessens M. The use of <sup>99</sup>Tc<sup>m</sup>-HSA dynamic vascular examination in the staging and therapy monitoring of reflex sympathetic dystrophy. *Nucl Med Comm* 1991; **12**: 725-731.
- 11 Tilman PBJ, Stadhouders AM, Jap PHK, Goris RJA. Histopathologic findings in skeletal muscle tissue of patients suffering from reflex sympathetic dystrophy. *Micron Microscop Acta* 1990; **21**: 271-272.
- 12 Goris RJA, van Dongen LM, Winters HAH. Are toxic oxygen radicals involved in the pathogenesis of reflex sympathetic dystrophy? *Free Rad Res Comm* 1987; **3**: 13-18.
- 13 Langendijk PNJ, Zuurmond WWA, van Apeldoorn HAC, van Loenen AC, de Lange JJ. Goede resultaten van behandeling van acute reflectoïre sympathische dystrofie met een 50% dimethylsulfoxide-creme. *Ned Tijdschrift Geneesk* 1993; **10**: 500-503.
- 14 Geertzen JHB, de Bruijn H, de Bruijn-Kofman AT, Arendzen JH. Reflex sympathetic dystrophy: early treatment and psychological aspects. *Arch Phys Med Rehabil* 1994; **75**: 442-446.
- 15 Salisbury RE, Loveless S, Silverstein P. Postburn oedema of the upper extremity - evaluation of present treatment. *J Trauma* 1973; **13**: 857-862.
- 16 Groenevelt F, Kreis RW. Burns of the hand. *Neth J Surg* 1985; **37**: 167-173.
- 17 Poplawski ZJ, Wiley AM, Murray JF. Post-traumatic dystrophy of the extremities. *J Bone Joint Surg* 1983; **65**: 642-655.
- 18 Goris RJA. Conditions associated with impaired oxygen extraction. In: Gutierrez G, Vincent JL (eds) *Tissue Oxygen Utilization*. Berlin: Springer Verlag, 1991; pp 350-369.

Paper accepted after revision 5 September 1995.

---

Correspondence should be addressed to: Dr L. van der Laan, Department of Surgery, University Hospital Nijmegen, PO Box 9101, 6500 HB Nijmegen, The Netherlands.