

## CASE REPORTS

# Successful Treatment of a Nine-Year Case of Complex Regional Pain Syndrome Type-I (Reflex Sympathetic Dystrophy) With Intravenous Ketamine-Infusion Therapy In a Warfarin-Anticoagulated Adult Female Patient

Ronald E. Harbut MD, PhD,\*† and Graeme E. Correll, BE, MBBS, FANZCA‡

\*Anesthesia Department, Page Hospital, Banner Health System, Page, Arizona; †Pain Management Program, Mayo Clinic Scottsdale, Scottsdale, Arizona; ‡Anaesthetics Department, Mackay Base Hospital, Mackay, Queensland, Australia

*Editor's Comment: This report of a single case study is presented in unusual detail because of the exceptional promise of the technique described, and the importance of further study. Complex Regional Pain Syndrome challenges our most informed and skillful interventions. The field is replete with reports of promising "cures" that fail to be replicated. We hope that this report will stimulate further studies of this intervention in carefully constructed studies of a larger series, with randomization, before conclusions can be drawn.*

### Introduction

Complex Regional Pain Syndrome (CRPS) is a painful and debilitating neuropathic pain disorder. CRPS is classified into two types [1]. Both types appear to occur after a traumatic event. With type-I, which is more common, no or only minor nerve damage may be detectable [2]. With type-II, however, clearly detectable nerve damage is usually evident [2].

Patients with CRPS frequently experience a devastating degree of never-ending burning pain that is life-altering [3]. The quality and intensity of the pain experienced in CRPS, in addition to the functional impairment that may ensue, often times threatens the very existence and reason to live for many individuals with this disorder. Conventional therapies are often only palliative; this is particularly true with patients who have suffered from CRPS, or whose underlying pathology remains undetected or untreated, for prolonged periods of time.

Reprint requests to: R.E. Harbut, MD, PhD, Page Hospital, P.O. Box 1447, Page, AZ 86040-1447. E-mail: ron.harbut@bannerhealth.com.

The early diagnosis and treatment of CRPS is essential to the amelioration of this disorder [3]. Multidisciplinary approaches to pain relief, now strongly encouraged, include the concomitant administration of physical therapy, exercise, and behavior modification. The mainstays of therapy include the administration of anticonvulsants, antidepressants, narcotics, sympathetic blocks, and topical anesthetics. The early use of implantable spinal cord stimulators has also been advocated [4]. Despite conventional treatment strategies, many CRPS patients continue to suffer from a significant degree of chronic ongoing pain, major disability, and adverse psychosocial consequences.

Unconventional therapies have also been tried for the treatment of CRPS and other neuropathic pain syndromes [5]. Such treatments have included the use of ketamine [6-8]. The basis for using ketamine to treat CRPS resides in ketamine's strong ability to block *N*-methyl-*D*-Aspartate (NMDA) receptors. Experimental evidence suggests that the symptoms of CRPS are mediated by a sufficiently intense or prolonged painful stimulus that causes an extraordinary release of glutamate from nociceptive first-order afferents onto second-order neurons within the spinal cord. The glutamate released, in turn, stimulates NMDA receptors on second-order neurons that produce windup and central sensitization phenomena [9-12]. Thus, it might be reasonable to conclude that by blocking NMDA receptors, one might also be able to block cellular mechanisms supporting windup and central sensitization phenomena [7].

With this in mind, Correll [13] envisioned that prolonged infusions of sub-anesthetic doses of ket-

amine might reverse abnormal cellular mechanisms that were maintaining CRPS. His early work over the last several years has strongly suggested this to be the case. He has observed that sub-anesthetic doses of ketamine can bring about, with minimal risk, a complete remission of CRPS pain in some patients, while being safely and efficiently given to fully conscious and fully ambulating inpatients on the general medical ward [13,14].

Below, we report the first successfully treated case of CRPS pain using this technique in North America.

#### Case Report

##### Past History

The patient is a 44-year-old female who presented with a nine-year history of chronic right leg and foot pain. Her medical history included a diagnosis of idiopathic thrombocytopenic purpura as a child that was no longer problematic after a splenectomy at 20 years of age. The patient had been on permanent disability since 1994, required the use of walking cane, and tried to have a productive and meaningful life at home raising her daughter and making arts and crafts.

The patient's history of pain began in 1992, when without any apparent triggering event, she developed the onset of intermittent episodes of "cramping" and "numbness" in her right distal lower extremity. The patient recalled that when a cramping sensation would begin, first her foot would turn white (starting at the toes), then her ankle, and finally, her leg. Subsequently her whole foot would go numb and develop a burning sensation. Relief of her pain and numbness, and a return of normal leg color, would occur after a few minutes of rest. These symptoms usually developed while walking but were also noticed even at rest or sitting. The patient also recalled that her right foot color was considerably "lighter" than the left. The patient's initial right lower extremity vascular studies were negative. The patient was given a diagnosis of Raynaud's disease and right-sided sciatica. Axial traction and analgesics were prescribed.

From 1992-1994, the patient's above intermittent symptoms continued. Lumbar trigger point injections were tried, but proved to be of no benefit. When the pain worsened, the patient sought additional medical attention. In 1994, an MRI of the lumbar spine was negative; however, repeat vascular studies revealed a 16 cm thrombus in the right femoral artery. Four balloon angioplasty attempts failed to restore blood flow to the femoral artery.

The patient was taken to surgery and a saphenous vein bypass was introduced. Afterwards, permanent anticoagulation therapy was begun with warfarin. Although the bypass relieved the cramping pain and restored some blood flow to the patient's leg, the burning pain persisted. Because of the severity of the patient's continuing pain and vascular compromise (at that time), she was unable to work and qualified for permanent social security disability. Although the patient was initially wheelchair dependent, she progressively improved to a walker and eventually a cane. The patient continued to use a cane when she walked to take some of the "pain" pressure off her right foot.

In 1994, the patient sought additional relief of her persisting pain from a rheumatologist and a local community pain center. A diagnosis of Reflex Sympathetic Dystrophy was given. Her subsequent treatment plan from 1994 through 1997 included: chiropractic care, physical and pool therapy, massage and healing touch, TENS unit therapy, acupuncture, narcotic analgesics, lumbar sympathetic blocks (3 injections), amitriptyline 50 mg daily (several months), gabapentin 900 mg three times daily (several months), sertraline 100 mg daily (several months), doxepin 50 mg daily (several months), and temazepam 15 mg at bedtime (several months). None of these treatments provided any durable relief of the patient's persisting pain. Methadone 10-50 mg daily was found to be useful on an intermittent basis. Sustained-release morphine up to 60 mg twice daily was also found to be useful by the patient initially, but its effectiveness waned after several months of use and the patient did not wish to continue with higher doses.

In 1997, the patient's symptoms were worsened by a return of her previous deep cramping pain. It was discovered that the patient's femoral artery bypass graft had occluded. Dissolution of the thrombus was successfully achieved with urokinase. Again, although the cramping pain was relieved, the burning pain remained.

From 1997-2000, the patient's burning pain was treated with another trial of amitriptyline 150 mg daily (several months), gabapentin 900 mg three times daily (several months), lumbar sympathetic blocks (2 injections), methadone 10-70 mg daily (on/off), fentanyl patches 25-100 mcg every 72 hours (although the patches were effective, the patient developed a skin rash to the adhesive backing), and three "emergency" outpatient epidural block injections consisting of local anesthetic which offered the patient at least a temporary relief of her symptoms for several hours at a time when her pain became excruciating (*i.e.*, 10/10).

In 2000, the patient's right lower extremity cramping pain returned. Her femoral artery bypass graft was again noted to have clotted. With the use of TPA, her occluded saphenous graft and previously thrombosed femoral artery were both successfully revascularized. For the first time since 1992, the patient commented that her right foot had "improved color," "pinked up," "was warmer," and had "much improved pulses." Unfortunately, even though her cramping pain resolved, her burning pain persisted.

From 2000 through 2001, the patient's burning pain persisted and she decided to return to a different local community pain center. The medications tried during this period included: venlafaxine 75 mg daily, methadone, nortriptyline, prednisone, felodipine, oxycodone, and carbamazepine. The only drug that consistently helped relieve her pain during this period was sustained-release oxycodone at a dosage of 80–120 mg daily, *i.e.*, 40 mg 2–3 times daily. She continued to require the use of a cane.

By mid-2001, she returned to her local pain center in the hope that a new pain relief might have become available. She was told that she had tried everything that was available to her at that facility and was referred to a large regional university pain center for possible further assistance. After the regional center reviewed the patient's history, she was told that further treatment was too risky and further treatment options were declined.

On December 26, 2001, the patient presented to Page Hospital (Page, Arizona) after learning from family living in the community that a treatment for CRPS using ketamine might be available to her. At the time of her admission, the patient had exhausted all conventional treatment options at other facilities. Since her symptoms of burning pain were intolerable and seriously impaired her quality of life, she wished to consider our alternate therapy.

#### *History on Admission*

On admission, the patient weighed 306 pounds and stood at a height of 5' 11.5". Her medications included: sustained-release oxycodone 40 mg 2–3 times daily; warfarin 7.5 mg alternating with 10 mg daily; aspirin 81 mg daily; and levothyroxine 0.2 mg daily.

The patient described a constant burning pain in her right leg and foot that ranged in intensity from 4–8/10. She stated that the pain was prominent on the anterior surface of her ankle and lower leg, and the dorsal and plantar surfaces of her right foot and toes. Walking any distance was stated to be difficult because, "the percussion" of her foot to the floor "was extremely painful." While riding in a car, the

patient needed to cushion her leg to ease the vibration. Her car was altered to have the accelerator pedal moved to the left side, even though the patient did not drive very often. She described a "deep bone-crushing pain" in her affected area. The patient also reported that the following experiences were very painful for her: "a dog licking her leg," "a child touching her skin," "shaving her leg," and "a gentle wind blowing on her skin." She also noted that clothes rubbing against her skin were very painful and that she preferred to have her blanket supported above her leg while she was sleeping. She also preferred to roll up her right pant leg so it was not touching her skin. She also commented that loud noises made her pain worse, and that she was unable to wear closed-in shoes.

#### *Exam*

The patient was found to be a pleasant, cooperative, very tall, and over-nourished 44-year-old female who appeared her stated age. Her vital signs on admission included: BP = 169/92, HR = 81, RR = 22, Temp = 99.3, SpO<sub>2</sub> = 96% (room air), Ht = 5'-11.5", Wt = 306 lbs. The patient was alert and oriented to person, place, and time. Patient was in moderate distress regarding use of her right leg and foot and used a walking cane. Her pupils were equally round. Extraocular movements were intact. Neck ROM was normal with regard to flexion, extension, and rotation. Her heart was with regular rate and rhythm, normal S<sub>1</sub> and S<sub>2</sub> heart sounds, and negative auscultatory findings for an S<sub>3</sub>, S<sub>4</sub>, or murmur. The patient's lungs were clear bilaterally, with breath sounds notably diminished in the posterior bases. There were some upper airway adventitious sounds that appeared to represent bronchitis secondary to the recent onset of an allergic reaction to cigarette and wood smoke.

The patient walked with an antalgic leftward tilt preferring to use a cane in her left hand and to bear weight on her left leg. She preferred to walk only on the heel of her right foot, trying not to allow the toes of her right foot to touch the floor. She otherwise demonstrated adequate balance when she walked.

The patient was assertively clear in mentioning that her right lower extremity was very sensitive to light touch, and did not readily wish to have her leg examined. Only one brief examination was permitted. On inspection, the patient's right ankle was notably swollen and about 20% larger than her left ankle. The patient stated this swelling was common and was reduced in the early morning when she awoke after having had her feet up in bed.

The anterior surface of her right ankle and lower leg demonstrated a mild reddish skin discoloration. Although the skin surface in this area had been shaved, the patient stated that the hair in this painful area was of a very fine texture when compared to the more coarse hair in the surrounding skin.

Very faint pulses were palpable on the dorsal surfaces of both feet (left > right). Both feet were equally warm to touch. The right foot was exquisitely painful to light touch. The patient remarked that her right foot pain increased from 4/10 to 9/10 during an assessment of her faint anterior tibial pulse. Posterior tibial pulses were not palpable. The patient's legs, feet, and toes were otherwise equally pink-to-ruddy in coloration.

#### Labs

A preliminary reading of a PA and lateral chest X-ray performed on admission did not appear to suggest any fluid in the fissures or costophrenic angles. The heart appeared to be of normal size.

On admission the CBC demonstrated a slightly elevated WBC of 11.5 (normal high = 11). Hemoglobin = 16.1. Hematocrit = 49.7. Platelets = 330. PT = 17.2. INR = 1.7 (target = 2.5). Comprehensive metabolic profile was essentially normal.

#### Impression

Impression on admission: (1) CRPS type-I of the right distal lower extremity; (2) s/p 1994 right saphenous vein bypass of right femoral artery thrombus; (3) s/p 1997 revascularization of right saphenous vein bypass; (4) s/p 2000 revascularization of right saphenous vein bypass and right femoral artery; (5) chronic warfarin anticoagulation therapy (target INR = 2.5); (6) borderline hypertension; and, (7) over-nourished 306 lb female (IBW = 160 lb) at increased risk for development of pulmonary atelectasis with prolonged bed rest.

#### Plan

Plan on admission: (1) internal medicine consult regarding patient's warfarin therapy and INR monitoring, and rule-out of upper respiratory tract infection before commencing ketamine therapy; (2) commence ketamine infusion therapy after informed consent; (3) incentive spirometry every 4 hours while awake for prevention of pulmonary atelectasis; (4) encourage ambulation as tolerated; (5) continue home analgesics including oral sustained-release oxycodone 40 mg 2-3 times daily; (6) taper sustained-release oxycodone if or as pain symptoms subside; (7) treat borderline hypertension as needed with oral meto-

prolol or clonidine; and, (8) treat any signs/symptoms of narcotic withdrawal with oral clonidine and other adjuncts as needed.

#### Treatment Course of Ketamine

Day #1. An infusion of ketamine was started at 1000 hours at a rate of 10 mg/hr and increased by 10 mg/hr every 2 hours as tolerated up to a maximum infusion rate of 30 mg/hr. Further increases were not pursued as the patient wished to remain "in control" and was beginning to perceive a mild feeling of inebriation. Every 2-4 hours while awake (for the duration of her treatment) the patient was asked to mark an "X" on a 10 cm visual analogue scale (VAS) indicating her current level of pain. Overall, the patient's pain level remained unchanged the first day with a VAS score of 4.5-5/10. Patient's medications included sustained-release oxycodone 40 mg twice daily, and warfarin 10 mg daily. When resting in bed, patient preferred to have her right leg propped up and exposed with nothing touching it.

Day #2. Ketamine infusion continued at 30 mg/hr. Pain level at 1000 hours was 4.5/10. VAS range for the day was 4-5/10. Patient noted that she no longer felt "a need" to take her regularly scheduled dose of sustained-release oxycodone 40 mg twice daily. Prior to the ketamine infusion, patient stated she typically noticed "increasing pain" as her "dosing time" approached. However, she noted that the prior evening's dose seemed to have stronger-than-usual effects. Because of this, the patient's dose of sustained-release oxycodone was reduced to 20 mg twice daily. Oxycodone/acetaminophen 5/325 was made available every 4-6 hours if needed for breakthrough pain.

Day #3. Ketamine infusion continued at 30 mg/hr. VAS score at 1000 hours was 3/10. Patient did well with the reduced sustained-release oxycodone dosage, requiring only one oxycodone/acetaminophen 5/325 during the night for breakthrough pain. Patient continued to feel a little inebriated, but was still "in control." At day's end, patient stated, "I've got toes again!" She said that she could actually let her toes touch the floor. Although her ankle and leg pain continued, its severity improved.

Day #4. Ketamine infusion continued at 30 mg/hr. VAS score at 1000 hours was 0.4/10. At 1400 hours, patient was resting in bed with a quilt pulled over both of her legs (the first time any blanket has been pulled over her right leg and foot in years). Toes, ankle, and leg were no longer in severe pain. No symptoms of allodynia or hyperesthesia remained. The patient was moved to tears of joy being happy about her improved condition. She also

*CRPS With Intravenous Ketamine-Infusion Therapy*

151

felt that the effect of the sustained-release oxycodone was excessive, so the dosage was decreased further down to 10 mg twice daily.

Day #5. Ketamine infusion continued at 30 mg/hr. VAS score at 1610 hours reached 0/10 for the first time during treatment and thereafter remained at 0/10. No leg/ankle/toe pain was appreciated. Some slight ankle "sensitivity" noted, but not pain. Patient experienced some narcotic withdrawal symptoms over the course of the night. Patient no longer required the use of her cane. Clonidine 0.2 mg twice daily was started for continuing narcotic withdrawal. Sustained-release oxycodone regimen was changed to 10 mg in AM and 20 mg in PM, with oxycodone/acetaminophen 5/325 available for breakthrough withdrawal. Decision was made to continue ketamine for an additional 24 hours.

Day #6. Ketamine infusion continued at 30 mg/hr until 1600 hours, when it was decreased to 20 mg/hr. Infusion rate decreased again at 1800 hours to 10 mg/hr. Infusion decreased to OFF at 2000 hours. Patient had no pain. VAS scores remained at 0/10. Patient kept for overnight observation.

Day #7. VAS scores remained steady at 0/10. Patient wished to be discharged home and was dismissed in stable condition on a taper schedule of sustained-release oxycodone and oxycodone/acetaminophen 5/325. Discharge medications included: clonidine 0.2 mg twice daily for controlling mild to moderate withdrawal symptoms; and, warfarin 10 mg daily for continued maintenance of her anticoagulation therapy. Patient remained in the community for 15 days before returning to her home in a neighboring state.

Follow-up at 1 week. Patient remained pain free and continued her narcotic taper. Clonidine was continued for withdrawal symptoms that included insomnia, restlessness, and diarrhea. Daily whirlpool therapy, long walks, and the use of a stationary exercise bike helped reduce her withdrawal restlessness. Loperamide was used daily to control her diarrhea. Insomnia occurred nightly and was calmed by additional whirlpool therapy. Patient was encouraged to channel daytime restlessness into demanding daily activities. It took several weeks for the patient's withdrawal symptoms to completely subside. The patient's anticoagulation prophylaxis remained well controlled on 10 mg warfarin daily.

Follow-up at 1 month: Patient remained pain free. Narcotics and clonidine were discontinued. Patient's quality of life was greatly improved by her new ability to pursue physical activities. She began to renew friendships and engage in social activities from which she had previously withdrawn. She was

very pleased. "Everything is possible again." "I have my life back."

Follow-up at 5 months. Patient remains pain free. No narcotics required. Patient continues to be very pleased and appreciative that she has been able to return to a normal painless life.

**Results**

The first sign of an improvement in VAS scores occurred during the second day of intravenous infusion. Although the patient's pain was persisting at this time, she noted that she did not feel "a need" to ask for her usually scheduled dose of sustained-release oxycodone. Prior to this, she always "knew" when 10-12 hours had elapsed from her last dose. As her infusion therapy progressed, she started noticing increased sedation after taking her sustained-release oxycodone. Because of this, her dose of sustained-release oxycodone was decreased by 50% (i.e., 40 mg to 20 mg twice a day) without an apparent aggravation of her baseline level of pain. Because of this reduction, her feelings of sedation decreased. Further decreases in narcotics were required as the ketamine treatment progressed into its fourth day of infusion. Oxycodone/acetaminophen 5/325 was available every 4-6 hours as needed for breakthrough pain as the sustained-release oxycodone dosage was reduced.

An actual decrease in the patient's level of pain was first noted after 48 hours of infusion therapy. The first sign of relief occurred in her toes. As time progressed, the patient's ankle and leg pain also steadily decreased and eventually resolved by 102 hours (Figure 1).

The patient noted the onset of a feeling of inebriation after the rate of ketamine infusion reached 30 mg/hr. As the infusion continued at this rate, this feeling eventually waned. During the patient's hospital stay, there were never any signs of unusual sedation. The patient visited with family and friends, ambulated around the nursing floor, and watched television as often as desired. All of the nursing staff participated in monitoring her progress, offered her encouragement, and were impressed by her slow but steady improvement. The patient never experienced any hallucinations, nightmares, or dysphoria.

As the patient's level of pain decreased, and as her daily dosage of sustained-release oxycodone was correspondingly reduced, a mild-moderate increase in restlessness was noted. This restlessness only appeared related to the progressive taper of her sustained-release oxycodone. This appeared to

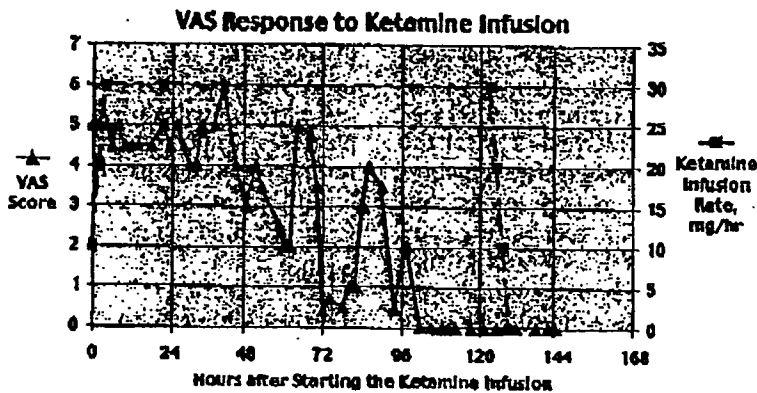


Figure 1 Time course of VAS response to a ketamine infusion over 6 days.

be the case since her withdrawal symptoms responded to supplemental doses of sustained-release oxycodone and/or oxycodone/acetaminophen and did not otherwise appear to be related to her continuing infusion of ketamine.

On admission, the day prior to the start of her ketamine infusion, the patient's blood pressure was mildly elevated and demonstrated notable variability. During her hospital stay, and during her infusion therapy and withdrawal of sustained-release oxycodone, her blood pressures continued to vary widely but also tended to be about 10–15% above baseline values. Metoprolol and, then later, clonidine was used to treat this blood pressure increase. Clonidine also served as a useful adjunct to treating her withdrawal symptoms from her decreased analgesic requirement for sustained-release oxycodone.

The patient required permanent warfarin anticoagulation prophylaxis prior to admission because of her right femoral artery bypass grafting and history of femoral artery thrombosis. On admission, the patient's INR was 1.7. She was on alternating doses of 7.5 and 10 mg doses of warfarin. An internal medicine consult was obtained. After a supplemental dose of warfarin 5 mg, the patient was placed on a daily dose of 10 mg. After approximately 5 days the INR was increased daily until warfarin to take effect, her daily INR stabilized and continued within her INR target range of 2–3 (reference standard units). There was no notable effect of ketamine on the efficacy or safety of her concurrent warfarin anticoagulation therapy.

Although increases in liver function enzymes have been observed to occur with infusions of ketamine more prolonged than 7 days [15], no such abnormalities occurred in this patient. Daily comprehensive metabolic profiles remained within normal limits.

Blood samples were taken during the treatment period to determine the corresponding plasma levels of ketamine and norketamine (Figure 2). These samples were sent to National Medical Services, Willow Grove, PA for analysis.

#### Discussion

During the last quarter of the 20th century, an increasing number of investigators creatively envisioned the use of noncompetitive NMDA receptor antagonists for the purpose of treating pain [16–24]. Although many drugs have some degree of NMDA antagonist activity (*i.e.*, dextromethorphan, amantadine, and methadone), ketamine is known to be the most potent representative clinically available. Even though ketamine was introduced as an intravenous anesthetic, it soon became apparent that it had intense analgesic properties.

With this in mind, researchers worldwide have explored the potential analgesic effects of NMDA receptor antagonists on neuropathic pain disorders, such as: CRPS [2,5,6], diabetic neuropathy [25,26], post herpetic neuralgia [27–32], and phantom limb pain [33–35]. Although analgesic effects have been observed with the use of ketamine, frequently these effects are short-lived or associated with CNS side effects including dysphoria, hallucinations, night terrors, or flash backs. The potential for causing hallucinations has been one of the greatest obstacles to using ketamine for the treatment of neuropathic pain syndromes.

In this case report, hallucinations did not occur. The patient was carefully titrated with slowly increasing doses of ketamine up to that level which just began to make her feel mildly inebriated. In

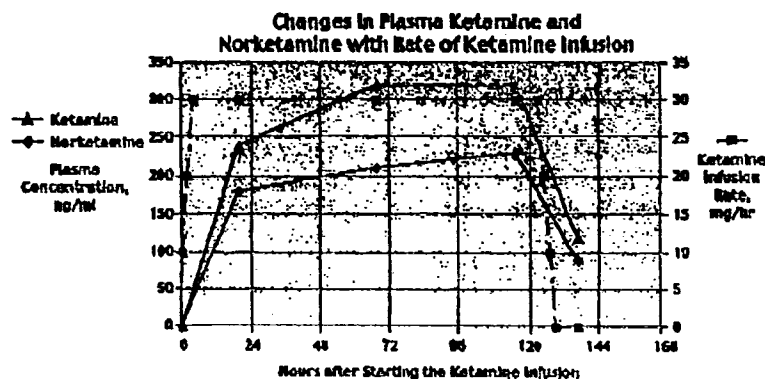


Figure 2 Time course of plasma ketamine & norketamine to a ketamine infusion over 6 days.

fact, the onset of the feeling of mild inebriation was our endpoint to cease any further increase in the infusion rate. Based on earlier work [13,14], we knew the effective infusion dosage would likely lie in the range of 10–30 mg/hr. We also knew that the effective treatment period on average would take about 2–5 days. Using these low-dose guidelines, we did not expect hallucinations to be likely.

In this case report, the patient never experienced hallucinations, dysphoria, or sedation. The maximal level of plasma ketamine attained during treatment was 320 ng/ml. This level is well below that seen when ketamine is used as a single-bolus anesthetic induction agent, *i.e.*, following a 2.2 mg/kg bolus, blood levels are reportedly 30,000 ng/ml at 30 seconds, and 1000 ng/ml at 10 minutes [36]. The patient did experience a period of mild inebriation that started several hours after her infusion began, lasted for 2–3 days, but then resolved even though her infusion continued. The patient otherwise did well with no other observable side effects. She remained ambulatory and conversant with the hospital staff, and regularly visited friends and family, and an especially attentive mother who regularly brought her gourmet meals.

The precautions taken to protect the patient during her hospital stay included daily comprehensive metabolic profiles to assure that no abnormalities in liver function developed. No changes were noted. Liver function tests (LFTs) were performed because Correll [15] previously noted occasional abnormalities in patients treated at infusion rates of ketamine  $\geq$  30 mg/hr given for  $\geq$  14 days. Correll further noted that all LFT abnormalities resolved when ketamine was discontinued.

Ketamine is not highly bound by plasma proteins [37], and thus, even though the patient was taking warfarin, no significant change in INR was ex-

pected. Daily INRs were taken and verified no effect of ketamine on this patient's anticoagulation status.

Since the patient weighed 306 pounds, additional precautions taken included incentive spirometry training and exercises every 2–4 hours while awake and continuous pulse oximetry monitoring from midnight–0800 hours while asleep. Mandatory supplemental humidified nasal O<sub>2</sub> at no less than 2 LPM was also provided between midnight–0800 hours. The nursing staff noted no ventilatory problems or episodes of nocturnal desaturation during the patient's hospital stay. Daily ambulation was encouraged.

Overall, the administration of this technique to treat CRPS was found to be: (1) relatively easy to conduct by hospital nursing staff with proper orientation; (2) convenient for the patient, aside for the inconvenience of inpatient hospitalization for proper monitoring; (3) without any untoward side effects with proper monitoring and precautions; and, (4) effective in completely relieving this patient's nine-year history of CRPS and restoring this patient to a normal life without the use of chronic medications, nerve blocks, or implantable devices.

In conclusion, we report the successful treatment of a patient with a nine-year history of CRPS type-I using a low-dose ketamine infusion technique. We believe the application of this technique may be useful in treating patients with chronic CRPS when more conventional treatments prove to be consistently ineffective, unnecessarily risky, or contraindicated.

#### References

- 1 Merskey H, Bogduk N. Classification of Chronic Pain: Description of Chronic Pain Syndromes and

- Definitions of Pain Terms, 2nd ed. Seattle: IASP Press, 1994.
- 2 Harden RN, Baron R, and Janig W. Complex Regional Pain Syndrome. Progress in Pain Research and Management, Volume 22. CRPS-I and CRPS-II: A Strategic View. IASP Press, Seattle, 2001; page 7.
  - 3 Schwartzmann RJ. New Treatments for Reflex Sympathetic Dystrophy. New England Journal of Medicine, 2000;343:654-656.
  - 4 Kemler MA, Barendse GAM, van Kleef, et al. Spinal cord stimulation in patients with chronic reflex sympathetic dystrophy. N Eng J Med. 2000;343:618-624.
  - 5 Backonja M, Arndt G, Gombar KA, Check B, Zimmerman M. Response of Neuropathic pain syndromes to ketamine: a preliminary study. Pain. 1994;56:51-57.
  - 6 Sang CN. NMDA-receptor antagonists in neuropathic pain: experimental methods to clinical trials. J Pain Symptom Manage. 2000;19:S21-5.
  - 7 Eide K, Stubhaug A, Oye I, Breivik H. Continuous subcutaneous administration of the N-methyl-d-aspartic acid (NMDA) receptor antagonist ketamine in the treatment of post-herpetic neuralgia. Pain. 1995;61:221-228.
  - 8 Ahmad M, Ackerman WE, Munir MA, Saleem M. NMDA Receptor Antagonists. Recent Advances in Chronic Pain. The Pain Clinic, April 2001, 25-31.
  - 9 Mendell LM. Physiologic properties of unmyelinated fiber projection to the spinal cord. Pain. 1966;41:309-321.
  - 10 Pockett S. Spinal cord synaptic and chronic pain. Anesth. Analg. 1995;80:173-179.
  - 11 Mannion RJ, Woolf CJ. Pain Mechanisms and Management: A Central Perspective. Clin J Pain. 2000;16:S144-S156.
  - 12 Carpenter KJ, Dickenson AH. NMDA receptors and pain—hopes for novel analgesics. Reg Anesth Pain Med. 1999;24:506-508.
  - 13 Correll GE. Personal communication and unpublished work. Anaesthetics Department, Mackay Base Hospital, Mackay, Queensland, Australia. Poster presentation at the 1999 Australian Pain Society Meeting, Fremantle, Western Australia.
  - 14 Correll GE, Muir JJ, Harbut RE. Use of ketamine infusion in patients with complex regional pain syndrome. J. Pain. 2002;3(2):p17 suppl.
  - 15 Personal observations by GE Correll during his initial ketamine infusion treatments from 1997-99.
  - 16 Ito Y, Ichiyonagi K. Post-operative pain relief with ketamine infusion. Anaesthesia. 1974;29:222-229.
  - 17 Clausen L, Sinclair DM, Van Hasselt CH. Intravenous ketamine for postoperative analgesia. S. African Med. J. 1975;71:539-542.
  - 18 Pandit SK, Kothary SP, Kumar SM. Low dose intravenous infusion technique with ketamine. Amnesic, analgesic and sedative effects in human volunteers. Anaesthesia. 1980;35:669-675.
  - 19 Sher MH. Slow dose ketamine—a new technique. Anaesth. Intens Care. 1980;8:359-361.
  - 20 Woolf CJ, Thompson SWN. The induction and maintenance of central sensitization is dependent on N-methyl-D-aspartic acid receptor activation: Implications for the treatment of post-injury pain hypersensitivity states. Pain. 1991;44:293-299.
  - 21 Per Kristian E, Jorum E, Stubhaug A, Bernnes J, Breivik H. Relief of post-herpetic neuralgia with the N-methyl-D-aspartic acid receptor antagonist ketamine: A double blind, cross-over comparison with morphine and placebo. Pain. 1994;58:347-354.
  - 22 Klepstad P, Borchgrevink PC. Four years treatment with ketamine and a trial of dextromethorphan in a patient with severe post-herpetic neuralgia. Acta Anaesth Scand. 1997;41:422-426.
  - 23 Hoffman V, Coppejans H, Vercauteren M, Adriaensen H. Successful treatment of postherpetic neuralgia with oral ketamine. Clin J Pain. 1994;10:240-242.
  - 24 Fisher K, Coderre TJ, Hagen NA. Targeting the NMDA receptor for chronic pain management: Preclinical animal studies, recent clinical experience and future research directions. J Pain Symptom Manage. 2000;20(5):358-373.
  - 25 Nelson KA, Park KM, Robinovitz E, et al. High dose dextromethorphan versus placebo in painful diabetic neuropathy and postherpetic neuralgia. Neurology. 1997;48:1212-1218.
  - 26 Sang CN, Parada S, Booher S, Et al. A double blinded randomized controlled trial of dextromethorphan versus memantine versus placebo in subjects with painful diabetic neuropathy and postherpetic neuralgia. Presented at 16th Annual Scientific Meeting at the American Pain Society; San Diego, CA, Nov. 1997.
  - 27 Eide PK, Jorum E, Stubhaug A, et al. Relief of post-herpetic neuralgia with the N-methyl-d-aspartic acid receptor antagonist ketamine: a double blind, cross-over comparison with morphine and placebo. Pain. 1994;58:347-354.
  - 28 Hoffman V, Coppejans H, Vercauteren M, Adriaensen H. Successful treatment of postherpetic neuralgia with oral ketamine. Clin J Pain. 1994;10:240-242.
  - 29 Kinoshita Y, Takakura K, Yanagimoto M, Fujibayashi T, Sugiura Y, Goto Y. Evaluation of ketamine infusion treatment for patients with chronic pain. Hokuriku J Anesthesiol. 1997;31:11-14.
  - 30 Tsuneyoshi I, Gushiken T, Kanamura Y, Yoshimura N. Changes in pain intensity of post-herpetic neuralgia following intravenous injections of ketamine hydrochloride. J Anesthesia. 1999;13:53-55.
  - 31 Wong CS, Shen TT, Liaw WJ, Cherng CH, Ho ST. Epidural coadministration of ketamine, morphine and bupivacaine attenuates post-herpetic neuralgia—a case report. Acta Anaesthesiologica Sinica. 1996;34:151-155.

- 32 Klepstad P, Borchgrevink PC. Four years treatment with ketamine and a trial of dextromethorphan in a patient with severe post-herpetic neuralgia. *Acta Anaesth Scand.* 1997;41:422-426.
- 33 Nikolajsen L, Hansen CL, Nielsen J, Keller J, Arendt-Nielsen L, Jensen TS. The effect of ketamine on phantom limb pain: a central neuropathic disorder maintained by peripheral output. *Pain.* 1996;67:69-77.
- 34 Nikolajsen L, Hansen PO, Jensen TS. Oral ketamine therapy in the treatment of postamputation stump pain. *Acta Anaesthesiol Scand.* 1997;41:329-31.
- 35 Mitchell AC. An unusual case of chronic neuropathic pain responds to an optimum frequency of intravenous ketamine infusions. *J Pain Symptom Manage.* 2001;21:443-6.
- 36 Donnelly AJ, Cunningham FE, Baughman VL. *Anesthesia & Critical Care Drug Handbook, 4th Ed. 2000-2001; 457-458.* American Pharmaceutical Association, Lexi-Comp, Inc. Hudson (Cleveland).
- 37 Hemelrijk JV, Gonzales JM, White PF. The protein binding of ketamine is 12%. *Principles and Practice of Anesthesiology, Volume I* Rogers MC, Tinker JH, Covino BG, Longnecker DE, eds. *The Pharmacology of Intravenous Anesthetic Agents.* St. Louis, Mo: Mosby; 1993: 1141.